

Deep Neural Networks for Automated Choroidal Tumor Segmentation in OCT Data

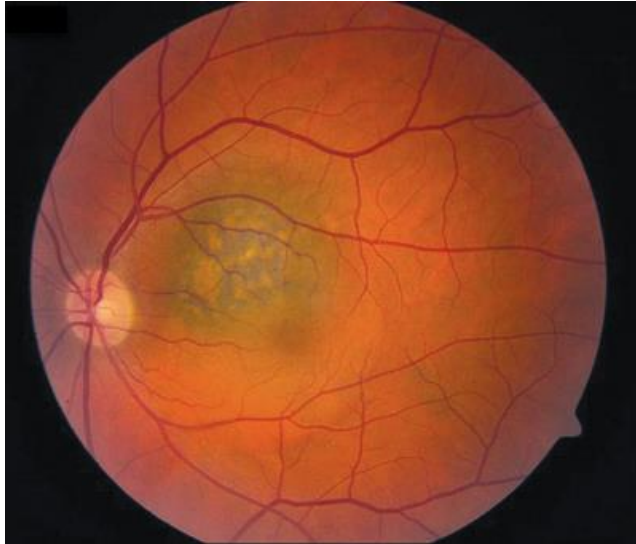


Figure 1: Ocular fundus photography of a choroidal tumor [1].

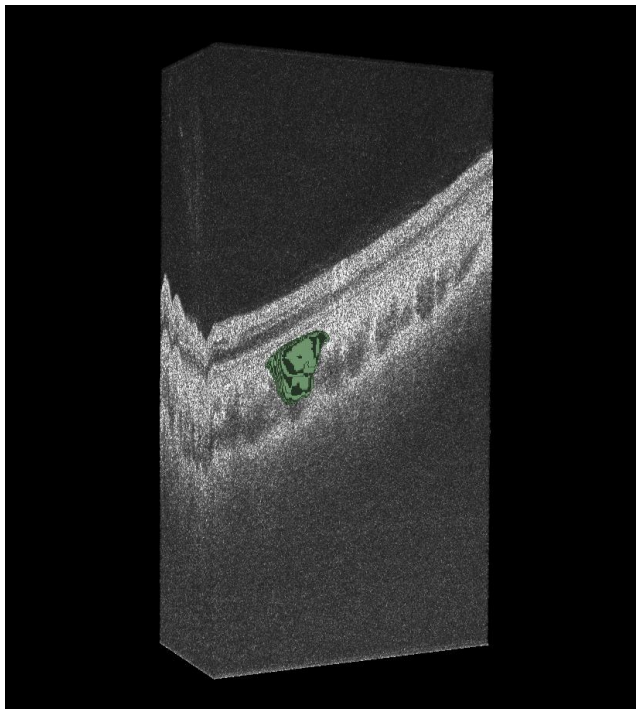


Figure 2: Tumor prediction (green overlay) with the MDGRU-3D_touchdown model in a 3D volume rendered OCT [2].

Master's thesis by Philippe Valmaggia for the Master of Science in Biomedical Engineering.

Machine Learning algorithms have improved a vast number of applications for medical image analysis, such as the segmentation of anatomical structures. The purpose of this thesis was the application, comparison and optimization of different segmentation algorithms with regard to choroidal tumors in Optical Coherence Tomography (OCT) images.

For this purpose, a binary pixelwise annotation for tumor and background was made for 121 OCT image stacks. The dataset consisted of 21 eyes with tumors and 100 eyes without and was split into training, validation and testing sets. Two deep neural network architectures were applied to the data; one is a Multidimensional Gated Recurrent Unit marked as MD-GRU, the other is a Convolutional Neural Network denominated as U-Net. Both networks were applied to the OCT data in 2D and 3D.

Segmentations of choroidal tumors were generated in 2D and 3D. The overall best performing network was a MD-GRU model denominated as MDGRU-3D_touchdown and achieved a DICE score of 0.76 on the testing set. This model relied on extensive data augmentation, loading a patch containing a tumor for every training step and downsampling of the original data to half the size in each dimension. The evaluation for a downsampled volume with a size of 128x496x256 pixels takes 4.5 minutes with the MDGRU-3D_touchdown.

This thesis presents the first automated segmentation of choroidal tumors in 3D compared to previous 2D segmentations. It could serve as proof of principle for segmentations of other pathologies in volumetric OCT data. Improvements on the used models are conceivable to meet clinical demands for the diagnosis and follow-up of choroidal tumors.

Advisor:

Robin Sandkühler
robin.sandkuehler@unibas.ch

Supervisor:

Prof. Dr. Philippe Cattin
philippe.cattin@unibas.ch

References:

[1] A. Cheung, I. Scott, T. Murray, and C. Shields, "Distinguishing a Choroidal Nevus from a Choroidal Melanoma", EyeNet Magazine, p.39-40, Feb 2012.

[2] P. Valmaggia, "Deep Neural Networks for Automated Choroidal Tumor Segmentation in OCT Data", MSc Thesis at the University of Basel, Apr 2020.