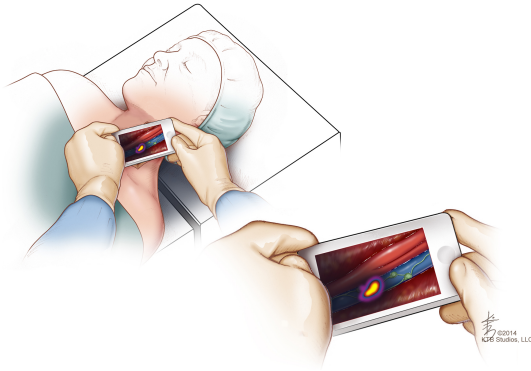


## INTRODUCTION

Morbidity from cancer is still high. This is especially true for squamous cell carcinoma in the head and neck region. To prevent the tumor from spreading, a complete removal of lymphatic tissue together with the tumor is often conducted. As has been shown by recent studies, such interventions are only required in roughly 30% of the patients. To avoid this overtreatment, a **sentinel lymph node biopsy** is necessary to correctly stage the malignancy [1].

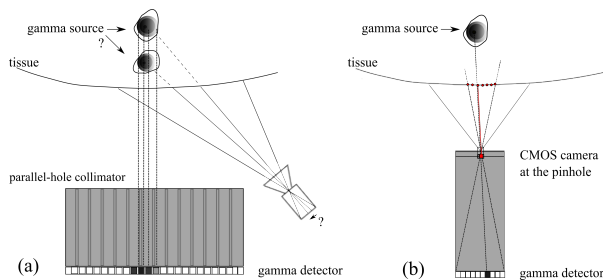
The poster describes the working principles and first tests of a **novel mobile AR scintigraphy device**.



This AR device **will help the surgeon to be more accurate** during sentinel lymph node biopsy to assess the tissue involved and to compare anatomical landmarks with the activity image for better orientation.

## METHODS


The device is sensitive to radioactive tracer-enriched lymph nodes. The emitted gamma rays are **collimated by multiple pinholes** and detected. An optical image of the biopsy site is simultaneously recorded by **an array of endoscopic cameras**.




In order to overlay the two modalities, the pinhole and the camera need the same opto-geometric mapping and aligned viewing axes to produce a corresponding **perspective projection** (b). This cannot be achieved using an orthographic projection without knowing the depth of the source (a).

## RESULTS


Preliminary augmentation results are presented for **one aligned camera/pinhole pair** in front of the collimator. A veil, containing the medical radioactive tracer liquid, is placed centrally at 3, 5 and 7 cm, respectively.



**Gamma activity** detector recordings of the radioactive veil for the three distances show an accumulation of radiation, mainly in the center.



For each of the distances, the gamma activity image patch of the central pinhole is **overlaid on top of the optical image** of its camera.



The **final augmented images**, thresholded and smoothed, show that the activity blob is scaled down with increasing distance.

## CONCLUSION

The **good spatial matching** of the gamma activity images with the corresponding optical images can be explained by the perspective projection model. As this model is valid for all pinhole-like collimating devices, the presented augmentation principle has the potential to provide a step forward for more accurate sentinel lymph node biopsy in general.

In a **next phase**, a calibration scheme needs to be devised and more of the camera/pinhole pairs need to be considered to improve and finalize the augmentation process.

## REFERENCES

- [1] Stephan K. Haerle and Sandro J. Stoeckli. SPECT/CT for Lymphatic Mapping of Sentinel Nodes in Early Squamous Cell Carcinoma of the Oral Cavity and Oropharynx. *International journal of molecular imaging*, 2011:106068, 2011.